Knowing the Congenital Heart Defects

Reed Halterman, DNP, CRNA
Associate Professor
Assistant Program Director
Augusta University

AUGUSTA UNIVERSITY

1

Objectives

- Participants will understand basic cardiac anatomy.
- Participants will understand the different congenital heart defects and their blood flow.
- Participants will have the knowledge to care for congenital heart patients in practice.

AUGUSTA UNIVERSITY

2

Congenital Heart Disease

AUGUSTA UNIVERSITY

3

Congenital Heart Disease

- Present in about 1% of newborn infants
- Causes
  - Idiopathic
  - Genetic
  - Environmental (rubella 1st trimester, lithium, FAS)
- Risk factors
  - Parent with CHD
  - Prematurity
  - Multiple gestations
  - Noncardiac congenital anomalies (Down's syndrome)

AUGUSTA UNIVERSITY

4

Signs & Symptoms

- Infants
  - Tachypnea
  - Failure to gain weight
  - Tachycardia (>200)
  - Heart murmur
  - Congestive heart failure
  - Hypoxemia
  - Cyanosis

Low oxygen levels in the blood cause the lips, fingers, and toes to look blue (cyanotic)

ADAM.

AUGUSTA UNIVERSITY

5

Signs & Symptoms

- Children
  - Dyspnea
  - Failure to grow
  - Decreased exercise tolerance
  - Heart murmur
  - Congestive Heart Failure
  - Cyanosis
  - Clubbing of digits
  - Squatting
  - HTN
  - Chest pain

AUGUSTA UNIVERSITY

6

Diagnosis

- Apparent during first week of life in 50% of afflicted neonates and before 5yrs in all remaining
- ECHO initial diagnostic test recommended
- Doppler US: demonstrates valvular dysfunction and septal defects
- CT/MRI scan: demonstrates anomalies involving great vessels
- Cardiac cath: most definitive diagnostic technique

AUGUSTA UNIVERSITY

7

Problems Afflicting Patient with CHD

- Various symptoms depending on defect
  - Pulmonary vascular disease & associated PHTN
  - Congestive heart failure
  - Infective endocarditis (VSD/PDA)
    - Requires prophylaxis antibiotics
  - Hypertension (Coarctation)
  - Polycythemia (HCT > 65%)
    - Physiologic response to chronic hypoxemia
    - Increase risk for thromboembolism
  - Coagulation defects
    - Deficiency in VT K clotting factors
    - Defective PLT aggregation
  - Brain abscess development

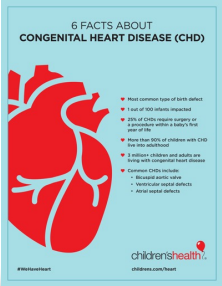

AUGUSTA UNIVERSITY

8

Pathophysiology

- Management of anesthesia for patients with CHD requires a thorough knowledge of the pathophysiology of each cardiac defect
- Confusing due to complexity of lesions
- Utilization of a structured approach that emphasizes ratio of pulmonary blood flow & systemic blood flow based on resistance in these vascular beds helpful

AUGUSTA UNIVERSITY

9

Pathophysiology

- Is there on obstruction?
  - R side
    - ↓ pulmonary blood flow
    - hypoxemia/cyanosis
  - L side
    - ↓ systemic blood flow
    - hypoperfusion/acidosis/shock

AUGUSTA UNIVERSITY

10

Pathophysiology

- Is there a shunt?
  - Mixing of pulmonary/systemic circulations
  - Direction of shunt determined by ratio of pulmonary blood flow (Qp): systemic blood flow (Qs)
    - Qp:Qs < 1: R to L shunt
    - Qp:Qs > 1: L to R shunt
    - Qp:Qs = 1: Balanced flow

AUGUSTA UNIVERSITY

11

Pathophysiology

- Shunt flow dependent on balance between PVR & SVR
  - ↑ PVR relative to SVR ⇒ R to L shunt
  - ↑ SVR relative to PVR ⇒ L to R shunt
- Factors affecting PVR and Qp:Qs Ratio
  - Increase PVR (R-to-L shunt)
  - Decrease PVR (L-to-R shunt)

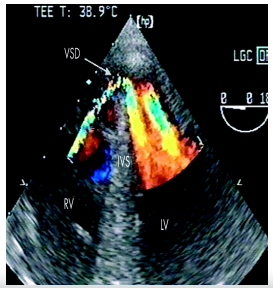

AUGUSTA UNIVERSITY

12

Classification of Congenital Heart Defects

- Lesions causing left-to-right shunting
  - Volume overload of the ventricle or atrium resulting in increased pulmonary blood flow
    - Atrial Septal Defect
    - Ventricular Septal Defect
    - Patent ductus arteriosus
    - Atrioventricular Septal Defect (Common complete atrioventricular canal)

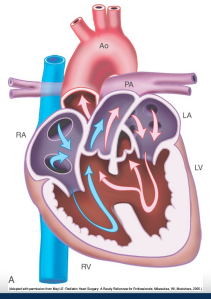

(Adapted with permission from Bing J-F. Pediatric Heart Surgery: A Ready Reference for Professionals. Milwaukee, WI: Marathon; 2008.)

13

Classification of Congenital Heart Defects

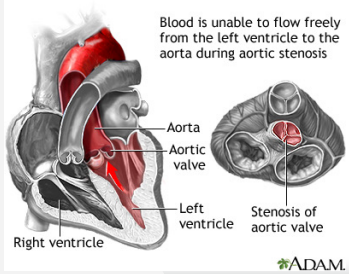

- Lesions causing outflow obstruction
  - Pressure overload on the ventricle, increased myocardial work
    - Aortic Stenosis
    - Coarctation of the aorta

14

Classification

- Lesions causing right-to-left shunting
  - Cyanosis resulting from obstruction/decreased pulmonary blood flow
    - Tetralogy of Fallot
    - Tricuspid atresia
    - Pulmonary atresia

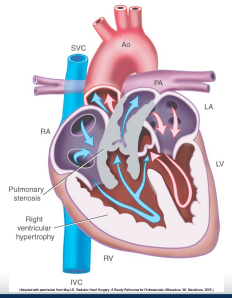

(Adapted with permission from Bing J-F. Pediatric Heart Surgery: A Ready Reference for Professionals. Milwaukee, WI: Marathon; 2008.)

15

Classification

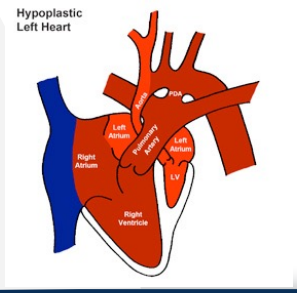

- Lesions causing right-to-left shunting
  - Cyanosis due to mixing of the pulmonary and systemic circulations/increase pulmonary blood flow
    - Hypoplastic left heart syndrome
    - Truncus arteriosus

16

Classification

- Lesions causing separation of the pulmonary & systemic circulations
  - Transposition of the great vessels

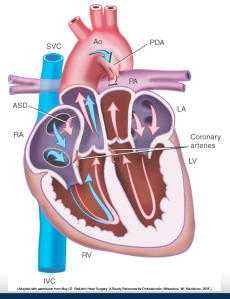

17

Classification

- Acyanotic (L→R)
  - Ventricular Septal Defect
  - Atrial Septal Defect
  - Patent Ductus Arteriosus
  - Atrioventricular Septal Defects
    - Common Complete Atrioventricular Canal
  - Aortic Stenosis
  - Coarctation of the Aorta
- Cyanotic (R→L)
  - Tetralogy of Fallot
  - Transposition of the Great Arteries
  - Hypoplastic Left Heart Syndrome (HLHS)
  - Tricuspid valve abnormalities (Ebstein's anomaly)
  - Truncus arteriosus
  - Total anomalous pulmonary venous connectio

18

Acyanotic

Predominantly Left-to-Right Lesions

19

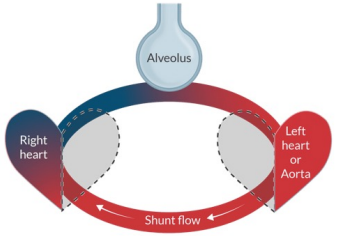

Pathophysiology

↓ Systemic blood flow
- Low cardiac output
- Hypotension

↑ Pulmonary blood flow
- Pulmonary HTN
- RVH

Hemodynamic goals

Avoid increased SVR

Avoid decreased PVR by avoiding:
- Alkalosis
- Hypocapnia
- High FiO_2
- Vasodilators

APEX ANESTHESIA REVIEW

20

Acyanotic: Predominantly Left-to-Right Lesions

- Simple shunts with isolated abnormal communications between the R & L side of the heart
- Pressure L side heart > Pressure R side heart ⇒ L-to-right shunt
  - Blood flow to R side heart & lungs increases
- Shunt flow depends on balance between PVR & SVR
  - PVR < SVR ⇒ L-to-R shunting
- Clinical manifestations
  - Pulmonary vascular congestion
  - Decreased lung compliance
  - Increased work of breathing
  - Chronic increases PBF
    - Irreversible ↑ PVR
    - RVH → Cor Pulmonale

AUGUSTA UNIVERSITY

21

Ventricular Septal Defect (VSD)

- Most common (25%)
- Shunt flow determine by PVR & SVR
  - ↓ PVR & ↑ SVR ⇒ ↑ L-to-R shunting
  - ↑ PVR & ↓ SVR ⇒ ↓ L-to-R shunting
- Clinical symptoms related to size of shunt
  - Small shunt produces none
  - Large shunt

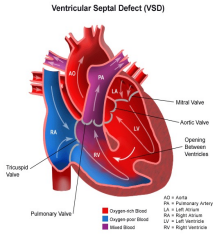

AUGUSTA UNIVERSITY

22

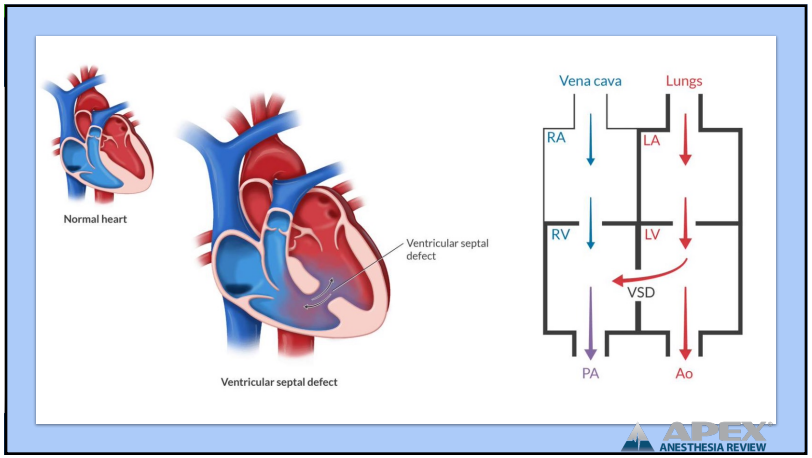

23

Ventricular Septal Defect (VSD)

- Treatment
  - Most small defects close w/o intervention (40% by 3yrs/75% by 10yrs)
  - Large defects require surgical closure before ↑ PVR irreversible
- Anesthetic considerations similar to ASD

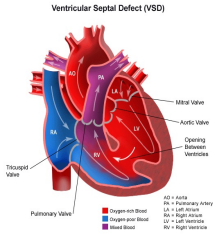

AUGUSTA UNIVERSITY

24

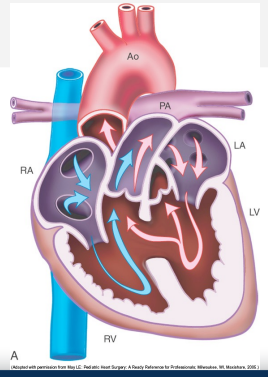

(Adapted with permission from May LC: Pediatric Heart Surgery: A Ready Reference for Professionals. Milwaukee, WI: Macsharp, 2006.)

AUGUSTA UNIVERSITY

25

Atrial Septal Defect (ASD)

- Accounts for 7.5% of CHD
- Most are asymptomatic (small) with spontaneous closure occurring in the 1st yr. of life
- Large defect
  - L to R shunt (pulmonary overflow)
  - Symptoms
    - DOE
    - SVT
    - CHF
    - Pulmonary HTN
    - Recurrent pulmonary infections
  - Requires surgical repair or placement of a device via catheterization

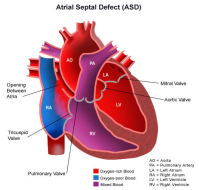

AUGUSTA UNIVERSITY

26

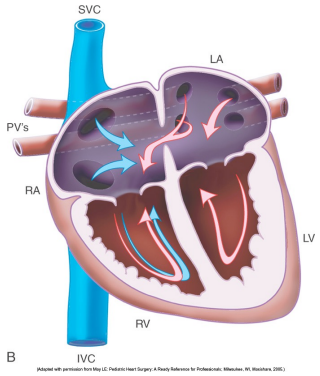

(Adapted with permission from May LC: Pediatric Heart Surgery: A Ready Reference for Professionals. Milwaukee, WI: Macsharp, 2006.)

27

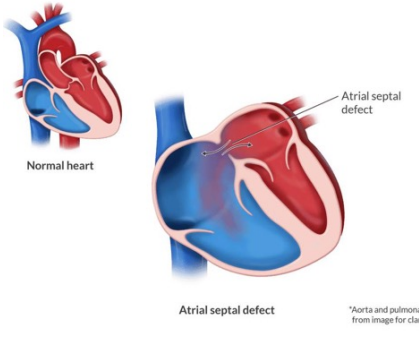

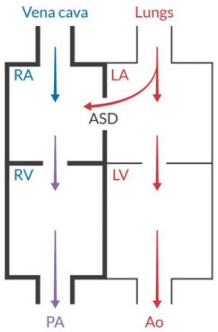

APEX ANESTHESIA REVIEW

28

Atrial Septal Defect

- Anesthetic considerations
  - Avoid ↑ SVR (worsen L-R shunting)
  - Avoid ↓ PVR (high FiO2, low ETCO2)
  - Strict avoidance of air emboli
  - L-to-R shunting's effect on rate of induction
    - More rapid with inhalation induction
      - Rapidly decreases the arterial to venous difference of agent
    - Slower rate of IV inductions
      - Dilutes arterial blood concentration

29

Patent Ductus Arteriosus (PDA)

- Failure of ductus arteriosus to close after birth (review fetal circulation and transition at birth!)
- Most common in the premature infant
- Accounts for 7.5% CHD
- Causes
  - Hypoxemia
  - Hypercarbia/acidosis
  - Persistent pulmonary HTN in the newborn
- Shunt flow determined by SVR & PVR
  - Nonrestrictive with SVR > PVR ⇒ L-to-R (blood flow from aorta back into pulmonary artery

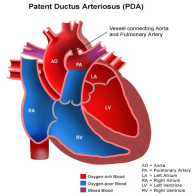

30

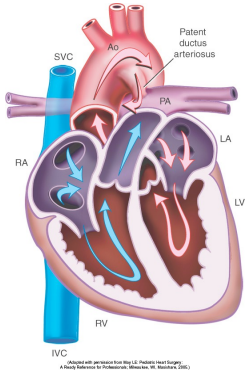

31

PDA

- Clinical presentation
  - Usually occurs 2-3 days after birth
  - Pulmonary congestion
  - CHF (widened pulse pressure, continuous systolic/diastolic murmur)
- Treatment
  - Medical: Indomethacin (↓ PGE1 levels)
  - Surgical ligation (NICU/Cath lab)
- Anesthetic considerations similar to ASD/VSD

32

Atrioventricular Septal Defects
Common Complete AV Canal

- Components
  - ASD & VSD
  - Single atrioventricular valve
- Common in children with trisomy 21
- Shunt flow
  - Bidirectional (mild hypoxemia)
    - Initial neonatal period (↑ PVR)
  - Predominantly L to R with ↓ PVR
- Symptoms
- Requires surgical repair within the 1st year of life

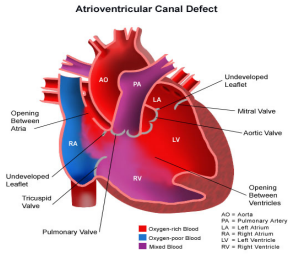

33

Obstructing Lesions

34

Congenital Aortic Stenosis

- Accounts for 5% of all CHD
- Anatomic/hemodynamic findings
- Symptoms related to severity of stenosis and ventricular function
  - Neonate with critical stenosis
  - Older children

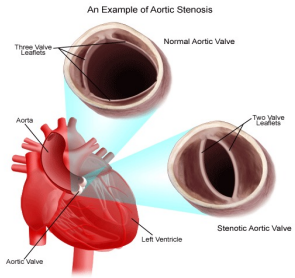

35

Congenital Aortic Stenosis

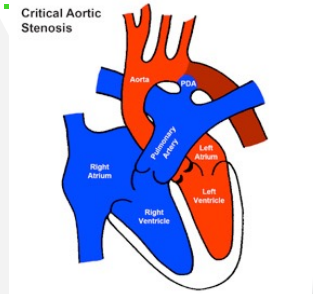

- Critical AS
  - Aortic valve opening cannot supply enough blood
  - Part of the blood supply to the body must be supplied by the PDA

36

Congenital Aortic Stenosis

- Surgical intervention
- Anesthetic management same as for the adult patient with aortic stenosis
  - Avoid sudden↓ SVR
  - Maintain NSR
  - Avoid bradycardia & tachycardia
  - Optimize volume to maintain venous return & LV filling pressures
  - Avoid hyperoxygenation
  - Controlled hypoventilation (↑ PVR)

AUGUSTA UNIVERSITY

37

Cyanotic Heart Defects

Predominantly Right-to-Left Shunts/Mixing Lesions

AUGUSTA UNIVERSITY

38

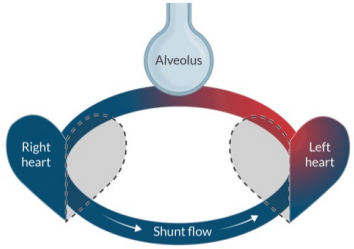

Pathophysiology

↓ Pulmonary blood flow
- Hypoxemia
- LV volume overload
- LV dysfunction

Hemodynamic goals

Maintain SVR
Decrease PVR
- Hyperoxia
- Hyperventilation
- Avoid lung hyperinflation

APEX ANESTHESIA REVIEW

39

Cyanotic Heart Defects

- Complex lesions
- Produce
  - Ventricular outflow obstruction
  - Intracardiac shunting
- Pulmonary blood
  - Decreased (TOF, Pulmonary atresia, Tricuspid atresia)
  - Increased (Transposition of the great vessels, Truncus arteriosus, Hypoplastic left heart)

AUGUSTA UNIVERSITY

40

Tetralogy of Fallot

- Most common CHD R → L shunt
- 3rd most prevalent CHD
- Anatomic defects
  - VSD
  - Aorta that overrides the pulmonary tract
  - Obstruction of pulmonary outflow tract
  - Right ventricular hypertrophy

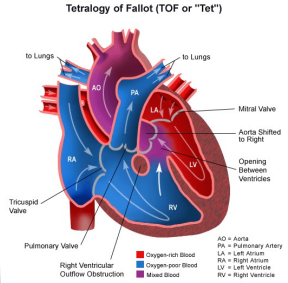

41

Tetralogy of Fallot

- Pathophysiologic characteristics
  - R-to-L shunting
  - ↓ Pulmonary blood flow
  - Polycythemia (>65%)
  - Ductal dependent pulmonary blood flow (L-R shunt) in neonate with severe obstruction (PGE1)

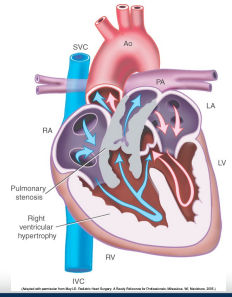

42

Tetralogy of Fallot

- Manifestations
  - Hypoxemia/cyanosis
  - Clubbing
  - Squatting (↑ SVR)
  - Ejection murmur
  - Hypercyanotic attacks ("tet spells")

Children with Tetralogy of Fallot exhibit bluish skin during episodes of crying or feeding.

43

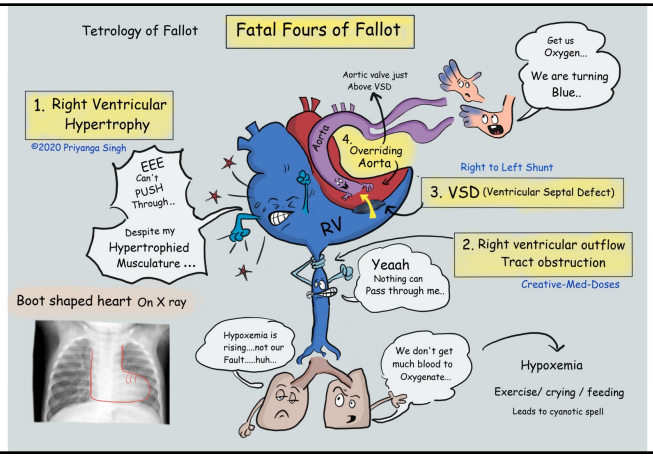

44

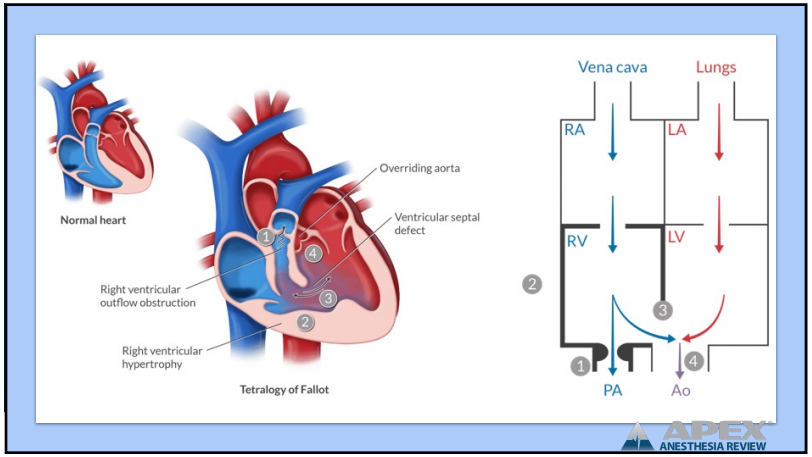

45

Tetralogy of Fallot

- Surgical palliation
  - Blalock-Taussig shunt
    - Left subclavian artery-pulmonary artery to increase pulmonary blood flow
- Complete correction
  - Closure VSD
  - Removal obstructing infundibular muscle
  - Pulmonic valvulotomy

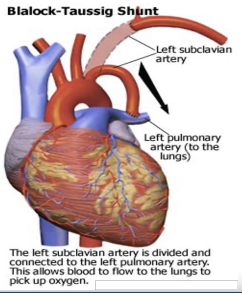

AUGUSTA UNIVERSITY

46

Tetralogy of Fallot

- Anesthetic management
  - Maintain intravascular volume
  - Maintain SVR/Avoid decreasing
  - Avoid ↑ PVR (acidosis, hypoxemia, excessive PIP)
    - Maintain higher FiO2 and lower ETCO2
  - Induction
    - Inhalation with pink patients
    - Ketamine IV/IM with cyanotic patients
  - R-to-L shunting effect on rate of induction?
    - Slows inhalational induction
      - Slows uptake
      - Dilutional effect
    - Accelerates onset in IV agents

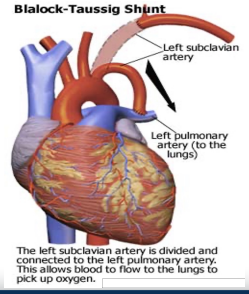

AUGUSTA UNIVERSITY

47

Schematic drawing of original Blalock-Taussig shunt on patient's right side and modified Blalock-Taussig shunt on left side.

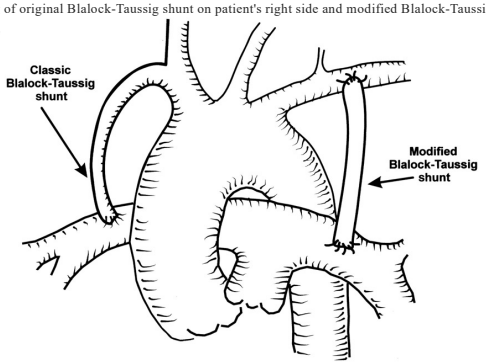

48

Tricuspid Atresia

- Absence of right atrioventricular connection
  - Severe hypoplasia or absent RV
  - Pulmonary blood flow dependent on PDA (L-R shunting)
  - LA & LV handle both systemic and pulmonary circulations
  - 90% associated with VSD allowing some blood to enter RV
  - Normal related great arteries or with transposition

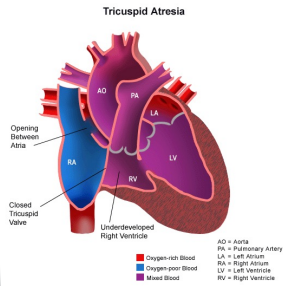

49

Tricuspid Atresia

- Clinical manifestations
  - Progressive cyanosis
  - Poor feeding
  - Tachypnea
  - CHF

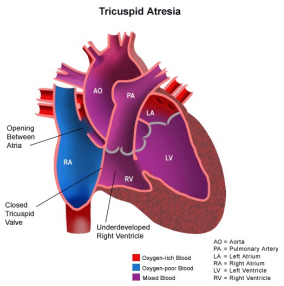

50

Tricuspid Atresia

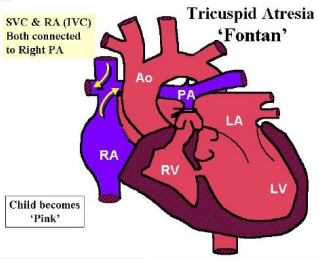

- Treatment
  - PGE1 to maintain pulmonary flow
  - Balloon atrial septostomy if atrial defect not sufficient
  - Surgical
    - Modified Blalock-Taussig shunt to maintain pulmonary blood flow
    - Cavopulmonary anastomosis (hemi-Fontan or bi-directional Glenn)
      - Redirection of IVC and hepatic vein flow into pulmonary circulation

51

Pulmonary Atresia

- Anatomical defect and physiologic effects
  - Absent pulmonary valve
  - RV hypoplasia
  - Tricuspid hypoplasia
  - Obligate atrial shunt from R to L
  - Ductal dependent pulmonary blood flow
  - Coronary artery-myocardial sinusoid communications

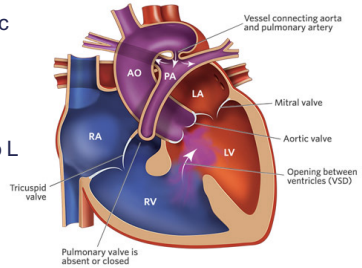

52

Pulmonary Atresia

- Manifestations
  - Severe cyanosis immediately after birth
  - Tachypneic
- Treatment
  - PGE1
  - Surgical
    - RV to PA conduit (coronary circulation is not RV dependent)
    - Blalock-Taussig shunt
    - Fontan palliation or heart transplant for RV-dependent coronary circulation

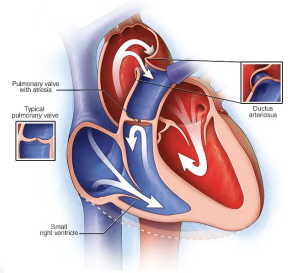

© MAYO FOUNDATION FOR MEDICAL EDUCATION AND RESEARCH. ALL RIGHTS RESERVED.

53

Transposition of the Great Vessels

- Accounts for 5% of all CHD
- Anatomical defect
  - Aorta arises from the RV → Deoxygenated blood returns back to systemic circulation
  - Pulmonary artery arises from the LV → Oxygenated blood returns back to lungs

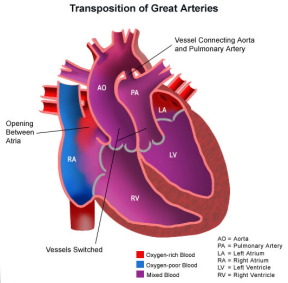

54

Transposition of the Great Vessels

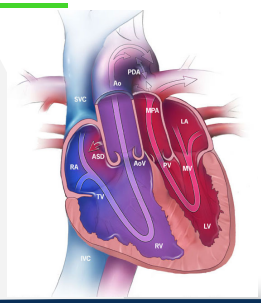

- Survival possible only if some form of intercirculatory mixing exists
  - PDA (PGE1 required)
  - Patent foramen ovale
  - ASD
- Variable degrees of pulmonary blood flow occur dependent on types of lesions present

55

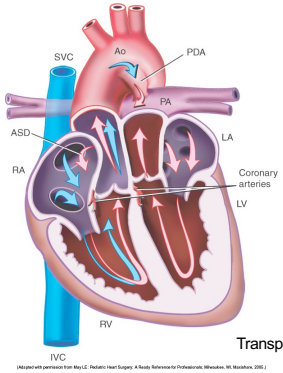

Transposition of the Great Vessels

[Adapted with permission from Mayo LE: Pediatric Heart Surgery: A Ready Reference for Professionals; Milwaukee, WI; Maxishure, 2005.]

56

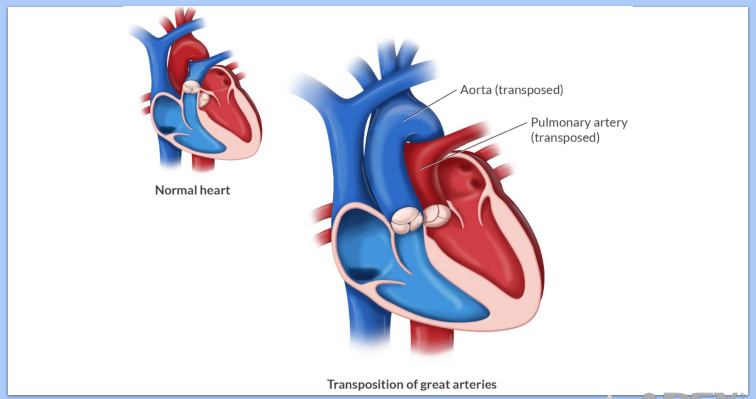

57

Transposition of the Great Vessels

- Corrective surgical treatment
  - Arterial switch with coronary artery reanastomosis
  - Atrial switch (Senning procedure)

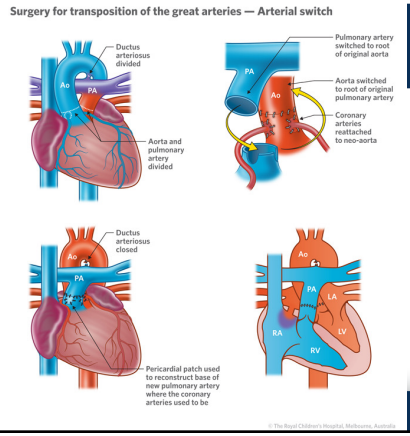

AUGUSTA UNIVERSITY

58

Transposition of the Great Vessels

- Anesthetic considerations
  - Maintain HR, contractility, preload, CO
  - TGV with ↓ PBF & minimal intracardiac mixing (ICM)
    - Avoid ↑ PVR relative to SVR (further reduce PBF and ICM
    - Adjust vent settings to ↓ PVR
      - ↑ FiO2 & RR
      - ↓ ETCO2
      - Maintain slight alkalosis
  - TGV with ↑ PBF & large ICM
    - Maintain normal PVR, ETCO2, low FiO2
    - Adjusting PVR will only modestly improve saturations at the expense of systemic circulation

AUGUSTA UNIVERSITY

59

Hypoplastic Left Heart Syndrome

- Anatomical defects
  - Underdeveloped LV
  - Aortic valve stenosis or atresia
  - Mitral valve stenosis or atresia
  - Hypoplasia ascending aorta

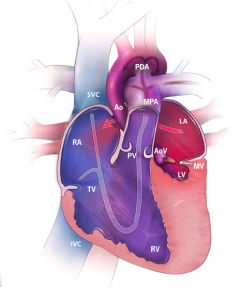

AUGUSTA UNIVERSITY

60

Hypoplastic Left Heart Syndrome

- Pathophysiologic effects
  - Blood flow to left side heart eliminated or reduced ⇒ obligatory L-to-R shunt
  - Systemic blood flow completely ductal dependant (R-L shunt)
    - All blood entering aorta derived from PDA
    - PGE1 essential
  - RV main pumping chamber for both pulmonary & systemic circulation
- Surgical correction
  - Palliative (Norwood, hemi-Fontan or bidirectional Glenn, completion Fontan)
  - Heart Transplantation

AUGUSTA UNIVERSITY

61

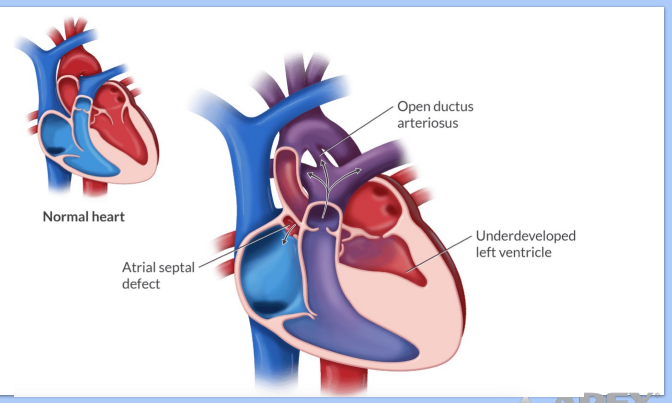

APEX ANESTHESIA REVIEW

62

Surgical Correction

- Norwood Procedure goals
- Utilize single right ventricle as systemic pump & reconstruct systemic arterial outflow
- Ensure pulmonary venous return to right heart
- Reroute systemic venous return directly to lungs
- ~ 70% 5-year survival of Norwood procedure

AUGUSTA UNIVERSITY

63

Stage 1 Norwood

- Usually done in the first few weeks of life
- Neoaorta constructed using divided main pulmonary artery (PA) anastomosed to aortic root
- Blalock-Taussig (BT) or Sano shunt created to provide blood flow to high-resistance pulmonary arterial circulation
- Ductus arteriosus ligated
- Atrial septum resected

AUGUSTA UNIVERSITY

64

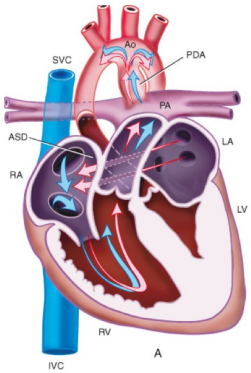
SVC
Ao
PDA
PA
ASD
LA
RA
LV
RV
IVC
A

65

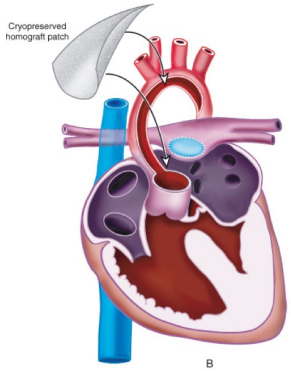
Cryopreserved homograft patch
B

66

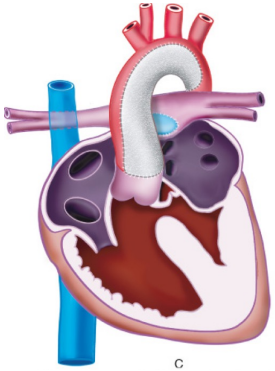
C

67

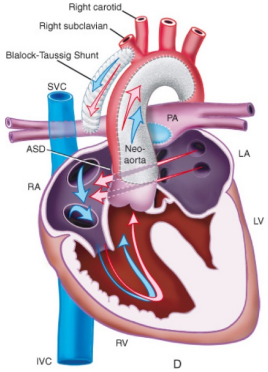
Right carotid
Right subclavian
Blalock-Taussig Shunt
SVC
PA
ASD
Neo-aorta
LA
RA
LV
RV
IVC
D

68

Stage 2 Norwood

- Around age 3–6 months
- BT or Sano shunt excised
- Bidirectional Glenn shunt created

AUGUSTA UNIVERSITY

69

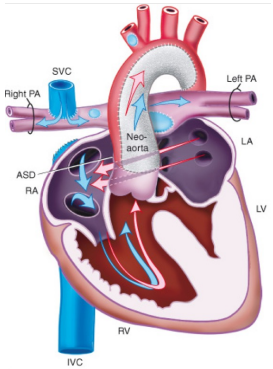

70

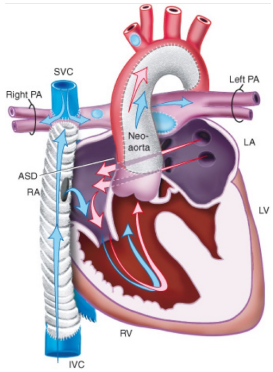

71

Stage 3 Norwood

- Around age 18–36 months
- Lateral tunnel or extracardiac Fontan procedure performed

AUGUSTA UNIVERSITY

72

Fontan Procedure

- "Fontan" Physiology
  - All venous blood returning to heart bypasses the right heart and flows passively into the lungs
  - RV pumps oxygenated blood returning from lungs into systemic circulation

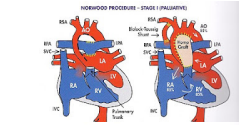

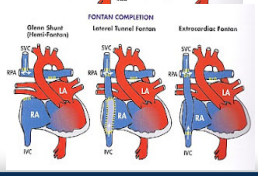

AUGUSTA UNIVERSITY

73

Fontan Procedure

- Anesthetic implications
  - Avoid ↑ PVR ⇒↓ PBF ⇒ hypoxemia
- Factors ↓ PVR/↑PBF
  - Hyperoxia
  - Alkalosis
  - HTN/↑ SVR
  - Low mean airway pressures
- Factors↑ PVR/↓ PBF
  - Hypoxemia
  - Acidosis
  - Hypotension/↓ SVR
  - PEEP

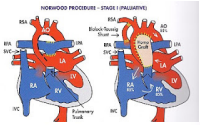

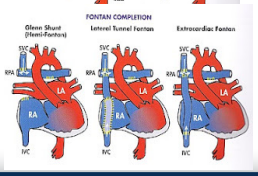

AUGUSTA UNIVERSITY

74

Summary

- Anesthesia providers will encounter patients with CHD for elective or emergent noncardiac surgery and during pregnancy
  - Unpalliated
  - Partially palliated (staged repairs)
  - Completely palliated (Fontan, Blalock-Taussig)
- Complete familiarization with the anatomic and hemodynamic function of the CHD is essential to formulating and managing a safe anesthetic plan

AUGUSTA UNIVERSITY

75

Summary

- Understand the impact of anesthesia management on the ratio of systemic to pulmonary blood flow also vital when formulating the anesthetic plan
  - What events ↑ SVR?
  - What events ↓ SVR?
  - What events ↑ PVR?
  - What events ↑ SVR?

AUGUSTA UNIVERSITY

76

77

References

- Apex Anesthesia Review.
- Barash, P. G. (2013). *Clinical anesthesia* (7th ed.). Philadelphia, PA: Wolters Kluwer Health/Lippincott Williams & Wilkins.
- Cannesson, M., Earing, M. G., Collange, V., Kersten, J. R., & Riou, B. (2009). Anesthesia for noncardiac surgery in adults with congenital heart disease. *The Journal of the American Society of Anesthesiologists*, *111*(2), 432-440.
- Fredenburg, T. B., Johnson, T. R., & Cohen, M. D. (2011). The Fontan procedure: anatomy, complications, and manifestations of failure. *Radiographics*, *31*(2), 453-463.
- Miller, Ronald D. Miller's Anesthesia. 7th ed. Philadelphia, PA: Churchill Livingstone/Elsevier, 2010.
- Morgan, G. E., Mikhail, M. S., & Murray, M. J. 1. (2006). Clinical anesthesiology (4th ed.). New York: Lange Medical Books/McGraw Hill Medical Pub.
- *Norwood procedure*. Norwood Procedure - an overview | ScienceDirect Topics. (n.d.). Retrieved February 23, 2023, from https://www.sciencedirect.com/topics/medicine-and-dentistry/norwood-procedure
- Stark, J. F., De Leval, M. R., & Tsang, V. T. (Eds.). (2006). *Surgery for congenital heart defects*. John Wiley & Sons.
- Stasik, C. N., Goldberg, C. S., Bove, E. L., Devaney, E. J., & Ohye, R. G. (2006). Current outcomes and risk factors for the Norwood procedure. *The Journal of thoracic and cardiovascular surgery*, *131*(2), 412-417.

AUGUSTA UNIVERSITY

78